

Fetal surgery for myelomeningocele: progress and perspectives

ENRICO DANZER | MARK P JOHNSON | N SCOTT ADZICK

Center for Fetal Diagnosis and Treatment, Children's Hospital of Philadelphia and University of Pennsylvania, School of Medicine, Philadelphia, PA, USA.

Correspondence to Dr Enrico Danzer at Center for Fetal Diagnosis and Treatment, 5th Floor, Wood Center, Children's Hospital of Philadelphia, 34th Street and Civic Center Boulevard, Philadelphia, PA 19104, USA. E-mail: danzere@email.chop.edu

PUBLICATION DATA

Accepted for publication 14th May 2011.

Published online 11th July 2011.

ABBREVIATIONS

fMMC Fetal myelomeningocele

MMC Myelomeningocele

MOMS Management of Myelomeningocele Study

Myelomeningocele (MMC), one of the most common congenital malformations, can result in severe lifelong disabilities, including paraplegia, hydrocephalus, Chiari II malformation, bowel and bladder dysfunction, skeletal deformations, and neurocognitive impairment. Experimental studies provide compelling evidence that the neurological deficits associated with MMC are not simply caused by incomplete neurulation but rather by the prolonged exposure of the vulnerable neural elements to the intrauterine environment. MMC is the first non-lethal anomaly considered for fetal surgical intervention, necessitating a careful analysis of risks and benefits. Retrospective and prospective randomized studies suggest that fetal surgery of MMC before 26 weeks of gestation may preserve neuromotor function, reverse hindbrain herniation, and reduce the need for ventriculoperitoneal shunting. However, these studies also demonstrate that fetal surgery is associated with significant maternal and fetal risks. Consequently, additional research is necessary to further elucidate the pathophysiology of MMC, to define the ideal timing and technique of fetal closure, and to evaluate the long-term implications of prenatal intervention.

Observations by obstetricians, paediatric surgeons, and neonatologists of infants who were born with irreparable organ damage led to the compelling rationale that the only way to prevent alteration of normal development was to correct the anatomical defect before birth.¹⁻³ Subsequently, the pathophysiology of specific fetal defects was delineated in experimental studies and anaesthetic, tocolytic, and surgical techniques for fetal surgical intervention were developed.¹ Ultimately, these efforts resulted in the clinical application of fetal surgical intervention starting in the 1980s.

During the initial period, prerequisites for fetal surgery were formulated that, with slight modification, still apply today.^{1,2} Although the fundamental concepts have not changed significantly in the past three decades, the ability to satisfy them for specific anomalies has improved dramatically. For instance, the available armamentarium for examining the fetus prenatally, including high-resolution ultrasound, ultrafast magnetic resonance imaging, and fetal echocardiography, when expertly applied, is capable of detecting essentially any significant fetal structural defect. When combined with maternal serum screening, karyotype analysis, and molecular screening techniques, the likelihood of missing an associated anomaly or performing an intervention on an unrecognized syndromic fetus has been dramatically reduced.

Further, our ability to safely operate on a mother and her fetus and correct selected congenital malformations has tremendously improved to the point at which open fetal surgery can be performed with reduced maternal morbidity and, to

date, no maternal mortality in centers experienced in such surgery.⁴

However, fetal surgical interventions have until recently been limited to fetal anomalies perceived to be lethal because of the potential risk of such a major surgical procedure to an otherwise healthy mother. The fetal surgical treatment of myelomeningocele (MMC), a non-lethal disorder, therefore extends the original prerequisites for fetal surgery to disorders causing irreversible organ damage before birth with associated quality-of-life morbidities after birth. This review will discuss the rationale for fetal MMC (fMMC) surgery based on our experience in the Center for Fetal Diagnosis and Treatment at the Children's Hospital of Philadelphia. This rationale is built on pathophysiological observations, animal models of MMC, and short-term outcomes from initial non-randomized experience with human fMMC closure, as well as the results of the recently completed National Institutes of Health-sponsored multicenter prospective randomized clinical trial, comparing outcome after prenatal and postnatal surgery for MMC.⁵

Pathophysiology and natural history of MMC

MMC is one of the most devastating congenital abnormalities that affect both the central and the peripheral nervous system.⁶ The defect is characterized by protrusion of the meninges and neural elements through a midline fusion defect of the caudal neural tube. Depending on the level, MMC results in various degrees of lower extremity paralysis, bladder and bowel incontinence, sexual dysfunction, and orthopaedic disabilities.

In addition to the spinal cord dysfunction, children with MMC almost invariably have an associated Chiari II hindbrain malformation, consisting of a small posterior fossa and downwards displacement of the cerebellar vermis below the foramen magnum into the cervical spinal canal, with elongation and compression of the brainstem and obliteration of the fourth ventricle.⁷ A significant percentage of children develop dysfunction of the cerebellum and medullary respiratory centre and cranial nerve disturbances.^{8,9} Despite aggressive medical and surgical intervention (e.g. shunt placement, laminectomy, and decompression of the craniocervical junction) 15 to 30% of neonates with MMC die within the first 5 years of life.^{8–11} In addition, obstruction of the outflow of cerebrospinal fluid from the fourth ventricle secondary to hindbrain herniation is believed to be the primary cause of hydrocephalus. The incidence of clinically significant ventriculomegaly associated with MMC ranges from 80 to 90%, and children are usually shunt dependent for life.^{12,13} Hydrocephalus negatively affects neurocognitive outcome and is associated with late morbidity and mortality owing to shunt malfunction and infection.

MMC can now be prenatally diagnosed as early as the first trimester,¹⁴ and extensive research into the natural history of MMC has elucidated genetic, environmental, and micronutrient causes.^{15–17} Considerable advances have been made in preventing MMC and other forms of neural tube defect,^{18,19} and many females of childbearing age are now aware of the important relationship between periconceptional folic acid supplementation and neural tube defects. Nevertheless, MMC still affects approximately 1 in 3000 live births, which translates to 1500 live-born MMC infants each year in the USA.²⁰ Not included in this figure are the estimated up to 50% of pregnancies affected by MMC in which the fetus is electively terminated.²¹

Although approximately two-thirds of affected individuals have an IQ of >80, less than 50% are able to live independently as adults and one-third continue to require substantial daily support.²² While recent cost estimates are not available, in 1994 the cost associated with the care for individuals with MMC exceeded \$500 million per year (in 1992 US dollars) in the USA alone.²³ Consequently, the emotional and financial impact of MMC not only for the individual, but also for the family and society, remain tremendous.

Rationale for fMMC surgery

Experimental and clinical studies suggest that the neurological deficits associated with MMC occur in stages: the two-hit hypothesis. First, defective spinal cord development during the fourth week of gestation results in a neural tube defect. Second, continuous exposure of the vulnerable neural elements to the amniotic fluid, direct trauma, hydrodynamic pressure, or a combination of these factors causes secondary damage in utero.

Starting in the early 1950s, histopathological studies of human embryos and fetuses with MMC in the earlier stages of gestation showed that the exposed neural elements were not neurulated but were otherwise well-developed anatomi-

What this paper adds

- This review provides a comprehensive overview of the rationale for fetal myelomeningocele surgery in the context of pathophysiologic observations, animal models, and clinical outcomes from non-randomized and prospective randomized experience with human fetal myelomeningocele closure.

cally.^{24,25} Interestingly, hindbrain herniation and ventriculomegaly were absent in the embryo specimens, but were found in several fetuses with MMC at a later stage of gestation. In subsequent examination of human fetuses and stillborn infants with MMC (19–25wks' gestation), varying degrees of neural tissue loss at the site of the lesion were observed, but the dorsal and ventral horns were normal proximal to the defect.^{26,27} More recently it has been postulated that ependymal denudation, which can be found in human MMC fetuses as early as 16 weeks of gestation, may precede or even trigger the development of secondary acquired injury to the exposed spinal cord as well as the development of MMC-associated hydrocephalus.^{28,29} Ependymal differentiation occurs in a well-orchestrated temporal and spatial pattern starting at about 4 weeks of gestation and is completed at approximately 22 weeks.³⁰ The fetal ependymal cells secrete important molecules and growth factors regulating neural proliferation, migration, and corticogenesis. When ependymal cells are lost (i.e. ependymal denudation has occurred), progenitor cells are lost and functional restoration may be impossible. Ependymal denudation is followed by macrophage invasion into the denuded areas, which subsequently causes increased inflammation, gliosis, and fibrosis at the denuded area. Hence, worsening of the pathological neurodevelopmental processes associated with MMC may occur.

Taken together, these studies indicate that the early stages of MMC development are characterized by non-neurulated but otherwise (near)-normal neural elements. There is a consensus that the prolonged intrauterine exposure of spinal cord tissue leads to progressive deterioration. Theoretically, fetal coverage might prevent or reduce the impact of the secondary component of the acquired damage. Thus, the controversy in the context of prenatal therapy arises over how much each of the two hits contributes to the observed neurological deficits and, from a feasibility standpoint, when during development the secondary damage occurs.

Additional support for the two-hit hypothesis came from multiple studies assessing lower extremity neuromotor function throughout pregnancy and during infancy, which demonstrated significant differences between prenatal and postnatal function. Korenromp et al.³¹ used sonography to document normal leg movement at 16 to 17 weeks in fetuses with MMC. Sival et al.³² compared the leg movements of 13 fetuses with MMC pre- and postnatally. Only one of the 13 had abnormal leg movements before birth, but 11 demonstrated abnormal leg movements postnatally.

Most newborns with MMC show neurological impairment at birth, suggesting that the neurological injury might occur later in gestation or even during delivery. Indeed, vaginal delivery has been associated with increased damage to the exposed neural elements resulting in poorer outcome when compared with infants delivered by Caesarean section.³³

Although some authors remain unconvinced regarding the causal relationship of vaginal delivery and increased neurological trauma, no group has compared vaginal delivery with elective Caesarean section for fetuses with MMC in a randomized, controlled fashion.³⁴

Finally, it should be noted that individuals with myelocystocele or other closed neural tube defects, in which the neural tissue is covered and protected by skin, have almost normal lower leg and continence functions, despite a defective neurulation that is nearly identical to that present in newborns with MMC.

Animal models for fMMC surgery

In addition to the multiple genetic^{35,36} and teratogenic³⁷ models of MMC and other neural tube defects, several models of mechanical disruption have been described. Michejda³⁸ developed a primate model in which a fetal lumbar laminectomy was performed at the L3 to L5 level. The study group was repaired immediately with allogeneic bone paste while a control group had no repair. The unrepaired fetuses showed cystic MMC-like lesions at birth and severe neurological impairment. In contrast, the group that underwent immediate repair was neurologically intact at birth. These studies unfortunately did not include monkey fetuses undergoing a period of in utero exposure of the lesion before it was closed. Heffez et al.^{39,40} reported similar findings in pig and rat fetuses. In both studies, surgical creation of an MMC-like defect with immediate or delayed surgical coverage allowed preservation of neurological function compared with the control group. These studies show that exposure of the vulnerable neural elements of the fetus to the intrauterine environment results in significant acquired neural tissue damage with corresponding neurological deficit at birth. In addition, these studies demonstrate that closure of a surgically created MMC-like lesion is feasible and improves neurological function at birth.

The surgical model that is most similar to simulating the human disease is the fetal lamb model of MMC introduced by Meuli et al.⁴¹ in 1994. The MMC-like defect was surgically created at 75 days of gestation (term 145–150d) by a lumbosacral laminectomy. Approximately 3 weeks after creation of the defect, a reversed latissimus dorsi flap was used to cover the exposed neural placode and the animals were delivered by

Caesarean section just before term. Human MMC-like lesions with similar neurological deficits were found in the control newborn lambs. In contrast, animals that underwent closure had near-normal neurological function and well-preserved cytoarchitecture of the covered spinal cord on histopathological examination. Despite mild paraparesis, they were able to stand, walk, and perform demanding motor tests, and demonstrated no signs of incontinence. Furthermore, sensory function of the hind limbs was present clinically and confirmed electrophysiologically.^{41,42} Russell Jennings at the University of California, San Francisco, and our group at the Children's Hospital of Philadelphia subsequently showed that this model, when combined with a lumbar spinal cord myelotomy, leads to the hindbrain herniation characteristic of the Chiari II malformation, and that in utero surgery restores normal hindbrain anatomy.^{43,44}

In addition to the fetal sheep model, we used our recently developed fetal rat model of retinoic acid-induced MMC in our laboratory to further characterize the pathophysiology of open spina bifida.⁴⁵ As previously reported,⁴⁵ rat fetuses exposed to retinoic acid develop MMC lesions that are usually confined to the lumbosacral area, covered by a cystic sac with abnormal spinal cord tissue on the dorsal aspect, and histologically demonstrate variable loss of neural tissue and areas of cord necrosis in the exposed segments, while the spinal cord and its coverings proximal to the defect remain normal (Fig. 1). Clinically, rat fetuses with MMC develop clubfoot deformity and abnormal bladder function, as well as hindbrain herniation on postnatal magnetic resonance imaging.^{45–47} Prenatal administration of retinoic acid induces a primary defect during neural tube formation. Therefore, our model allows evaluation of the development of neurological abnormalities in MMC from the point of abnormal neurulation onward. Consequently, using this animal model we were able to provide clear evidence that, despite a failure in neurulation early in gestation, normal functional development of the exposed spinal cord can occur.⁴⁸ We also demonstrated that loss of this function is associated with increased neurodegeneration that is acquired during later gestational stages, and we showed that the degree of neurological dysfunction correlates with the concentration of glial fibrillary acidic protein levels with the amniotic fluid as gestation proceeds in fetuses with MMC.⁴⁸

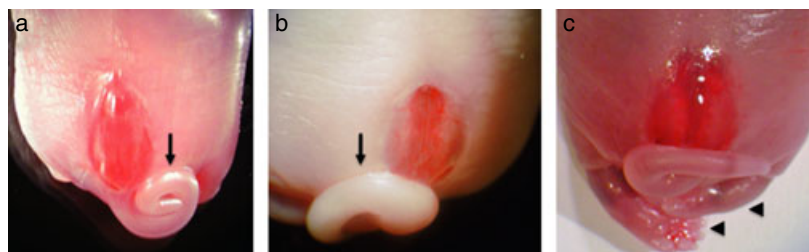


Figure 1: Representative photographs of retinoic acid-induced lumbosacral myelomeningocele (MMC) defects in rat fetuses at term (embryonic day 22; a–c). Similar to human fetuses with MMC, a thin fibrous membrane covers the defect. Various degrees of curly or bent tail (black arrows) as well as clubfoot deformities (black arrow head) are noted.

Non-randomized fetal surgical intervention for MMC

The first case of fMMC surgery was performed in 1994 using an endoscopic approach.⁴⁹ This technique proved disastrous (two of four fetuses died) and was abandoned. Subsequently, Farmer et al.⁵⁰ from the University of California, San Francisco, reported on three individuals who underwent fetoscopic fMMC surgery. Fetoscopic coverage was successfully completed in one individual. However, the patch partially detached after fetal intervention and the newborn required standard repair and shunt placement postnatally. Owing to technical difficulties, the MMC defect in the second fetus was never completely covered and the fetus delivered prematurely at 31 weeks of gestation. Postnatally the newborn required neurosurgical repair of the lesion and ventriculoperitoneal shunt placement and subsequently died of urosepsis at 1 month of age. The third fetus required conversion to an open approach secondary to an anterior placenta and difficulties in appropriately positioning the fetus. Fetoscopic patch coverage has also been tried in Europe in a small number of individuals where it has also proved enormously problematic.⁵¹ The same group more recently reported outcomes on 16 additional fetuses that underwent fMMC surgery using a fetoscopic approach.⁵² However, the results remain disappointing. Complete coverage of the defect was achieved in only 11 (69%) fetuses. In four fetuses the surgery was terminated before completion of the procedure secondary to hemorrhaging at the trocars side. Mean age at delivery was 28 weeks, which is considerably lower than the reported mean gestational age at delivery for the open approach.⁵ Oligohydramnios was found in nine (56%) pregnancies. Overall survival was only 81% (severe prematurity, $n=1$; intraoperative demise, $n=1$; termination of pregnancy after fetal intervention, $n=1$).

The first successful (i.e. resulting in improved postnatal neurological function) open fMMC surgery in an early gestation human fetus was performed by our group in 1998.⁵³ A 23-week gestation fetus with a thoracic level lesion, hindbrain herniation, and normal lower extremity movement, assessed by preoperative high-resolution ultrasonography, underwent open surgical coverage of the dysraphic defect. Fetal intervention and recovery were uneventful, and the fetus was subsequently delivered by Caesarean section at 30 weeks of gestation after the onset of preterm labour. After delivery the infant had a right clubfoot deformity, with function at the L4 level on the right and L5 level on the left. Whereas hindbrain herniation was found preoperatively, postnatal magnetic resonance imaging confirmed hindbrain herniation reversal and absence of ventriculomegaly; therefore, shunting was not required.

The preoperative counselling as well as the intraoperative and postoperative management algorithm for fMMC surgery has been extensively covered by the recent Management of Myelomeningocele Study (MOMS) trial publication.⁵ In general, the fetus is carefully positioned with the lesion visible through the uterine incision (Fig. 2). The cystic membrane of the MMC is excised carefully under magnification and fetal surgery is performed as described elsewhere.⁵

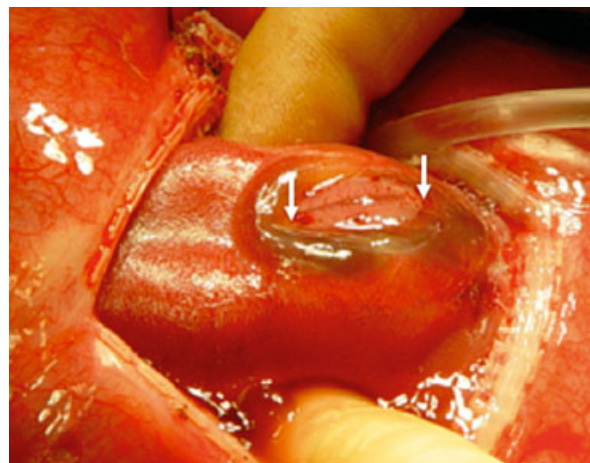


Figure 2: Exposure of a 23-week gestation fetus through hysterotomy showing the myelomeningocele lesion. The white arrows identify the neural placode.

Subsequent studies from the Children's Hospital of Philadelphia and Vanderbilt University suggested that infants treated prenatally had improvement in hindbrain herniation as early as 3 weeks post fMMC surgery and had a diminished need for shunting relative to infants who underwent standard postnatal neurosurgical repair.⁵⁴⁻⁵⁶ Compared with historical controls, it was estimated that fMMC surgery reduced the need for ventriculoperitoneal shunt placement by more than 30%.⁵⁴ The functional significance of the more normal position of the hindbrain, reduced shunt rate, and the restoration of near-normal cerebrospinal fluid hydrodynamics^{57,58} is that the majority of children with fMMC have no or only mild brainstem compression symptoms at 6 years of age.^{59,60}

Recent evaluation of children who underwent fMMC surgery at the Children's Hospital of Philadelphia showed that 57% of these neonates had lower extremity neuromotor function that was better than predicted by a median of two functional levels and 24% had neuromotor function as predicted, while 19% had worse than predicted function by a median of one functional level.⁶¹ These follow-up studies also revealed that 69% of children with fMMC were independent walkers at a mean follow-up age of 5 years 6 months.⁶¹ However, these children often continue to demonstrate coordinative deficits and gait disturbances that are characteristic for MMC. Despite these promising findings, there is already concern that some of the early benefits of fMMC surgery may be at risk. Recently some individuals have developed clinical symptomatic spinal cord tethering in association with dermoid inclusion cysts at the fetal closure site and required repeat surgery.⁶² A possible late decline in neurological function due to tethering with or without dermoid inclusion cysts underscores the importance of careful long-term neurological surveillance of these children.

Regarding preschool neurocognitive outcome, 30 of the initial 54 survivors of fMMC (56%) at our institution underwent standardized preschool neurodevelopmental assessment.⁶³ At

a mean follow-up age of 5 years 1 month, the majority of children with fMMC had neurocognitive scores in the average to high-average range and were at an age-appropriate point in schooling. Although children with fMMC who did not require ventriculoperitoneal shunting were more likely to have better outcomes, there was a consistent pattern for the entire cohort of higher scores in the verbal areas compared with scores for visual motor or non-verbal learning skills. These findings suggest the possibility of later learning difficulties.

Although long-term follow-up of these children into adulthood is necessary, the implications of the short-term outcomes after fMMC repair are significant, but not without controversy. The potential morbidity and mortality resulting from fetal surgery is real, and it is unclear whether the early demonstrated benefits will be sustained into adulthood. While data suggest that closure earlier in gestation may have greater benefits, the optimal timing of surgery is unclear, as is the optimal type of closure. In addition to the above-mentioned risk for the fetus, maternal-fetal surgery has postsurgical and future risks for the mothers. Potential maternal risks include surgical bleeding, infection (wound, amniotic cavity), preterm rupture of membranes, preterm labour and delivery, medication and anaesthesia complications, prolonged hospitalization, and the need for repeat Caesarean deliveries for all future pregnancies.^{1,2,64}

Randomized fMMC surgery – the Management of Myelomeningocele study

Owing to the lack of a control group of children with MMC who did not undergo prenatal surgery, the initial clinical results of fMMC surgery have been compared with previously published cohorts. Infants treated prenatally represent a highly selected subset of affected individuals. Comparison between individuals with MMC who were treated prenatally and previously reported controls are subject to substantial bias. For these reasons, the National Institutes of Health sponsored a multicenter prospective, randomized clinical trial, comparing outcome after in utero and postnatal surgery for MMC beginning in 2003, which recently stopped enrolment after recruitment and randomization of 183 of a planned sample size of 200 individuals because of efficacy of fetal surgery.⁵ The study was performed by three fetal surgery units (Children's Hospital of Philadelphia, Vanderbilt University, and University of California, San Francisco), the Data Study and Coordinating Center at George Washington University, and the Eunice Kennedy Shriver National Institute of Child Health and Human Development. The objective of the trial was to evaluate whether intrauterine coverage of MMC between 19 and 25 weeks of gestation improves outcomes compared with standard neurosurgical repair. One primary outcome was a composite of fetal or neonatal death or the need for ventriculoperitoneal shunt placement by the age of 12 months. A second primary outcome was the assessment of cognitive development and motor function at 30 months. A variety of secondary neonatal and maternal outcome measures were also examined. Similar to the earlier non-randomized results of individuals who underwent fMMC repair, the MOMS trial

showed a significant reduction in ventriculoperitoneal shunt placement at 1 year of age following fMMC surgery (prenatal group 40% vs postnatal group 82%; $p < 0.001$). The trial also demonstrated a substantial improvement in the overall neuro-motor function at 30 months of age by a variety of measures, including the finding that 42% of fMMC children were walking independently compared with only 21% in the postnatal group ($p < 0.01$). Finally, hindbrain herniation was significantly reversed in the fMMC surgery group compared with the postnatal surgery group (no hindbrain herniation in 36% and 4% of the infants respectively, and severe herniation in 6% and 22% respectively, $p < 0.001$). Ongoing follow-up of these children will provide further information regarding the impact of fMMC surgery on mental capacity, bladder and bowel continence, and sexual function.

Despite these promising results, the MOMS trial also revealed that fMMC surgery increases the risks for spontaneous rupture of membranes (prenatal surgery 46% vs postnatal surgery 8%; $p < 0.001$), oligohydramnios (21% vs 4%, $p = 0.001$), and preterm delivery (79% vs 15%; $p < 0.001$), including 13% of fMMC children who were born before 30 weeks of gestation. The average gestational age at delivery in the fetal group was 34.1 weeks of gestation compared with 37.3 weeks in the postnatal surgery group. Also, at the time of delivery, approximately one-third of mothers in the fMMC group demonstrated evidence of thinning of the uterine wound or variable degrees of dehiscence at the hysterotomy site, but none had a hysterotomy rupture.

Future perspective on fMMC surgery

A number of fundamental requirements will impact on the future success and expansion of fMMC surgery. First, the

Table 1: Inclusion and exclusion selection criteria based on the Management of Myelomeningocele Study trial recommendation⁵

Inclusion criteria	
Maternal age	≥18y
Gestational age at randomization	19wks, 0d–25wks, 6d
Normal karyotype	
S1-level lesion or higher	
Confirmed Arnold–Chiari II malformation on prenatal ultrasound and magnetic resonance imaging	
Exclusion criteria	
Multiple gestation pregnancy	
Insulin-dependent pregestational diabetes	
Additional fetal anomalies unrelated to MMC	
Fetal kyphosis	≥30 degrees
History of incompetent cervix and/or short cervix	<20mm by ultrasound scan
Placenta previa	
Other serious maternal medical condition	
Obesity defined by body mass index of	≥35
Previous spontaneous singleton delivery	<37wks' gestation
Maternal–fetal Rh isoimmunization	
Positive maternal human immunodeficiency virus or hepatitis B or known hepatitis C positivity	
No support person to stay with the pregnant women at the centre	
Uterine anomaly	
Psychosocial limitations	
Inability to comply with travel and follow-up protocols	

MMC, myelomeningocele.

results of the non-randomized and randomized studies regarding prenatal therapy for MMC are less than perfect,⁵ and it is clear that prenatal surgery is not a cure for MMC. Despite fetal closure, 40% still required shunting, but not all experienced improved neuromotor function or complete reversal of hindbrain herniation, and only time will tell if these findings persist. As such, continued long-term follow-up is therefore of utmost importance to assess the durability of the initial benefits. The follow-up of the entire 183-participant MOMS trial cohort at 12 and 30 months of age is important, and analysis of any prenatal anatomical predictors of favourable outcome needs to be delineated. In addition, a follow-up study of the MOMS trial participants at 6 to 10 years of age has been funded by the National Institutes of Health.

Second, the results of our follow-up studies cannot be generalized to individuals who will undergo fMMC surgery at centers with less experience of the technique or individuals who will have fetal intervention outside the eligibility criteria set forth by the MOMS study (Table I). Outcomes may be less favourable than those in the trial, and maternal and fetal complications would be expected to be greater as part of the recognized early 'learning curve' at new centers. Hence, for the safety of the individuals concerned and for optimal outcome,

fMMC surgery should initially be limited to high-volume fetal surgery centers with an interdisciplinary team of experts following a standardized protocol to perform fMMC surgery until other regional centers develop experience and expertise in such procedures.

Finally, the timing and technique of fMMC surgery needs to be optimized. The development of minimally invasive approaches for fMMC surgery might not only minimize pre-term labour and delivery, but would also allow prenatal coverage of the lesion much earlier than currently performed. Our research laboratory recently evaluated gelatin-hydrogel based scaffolds for early gestation prenatal coverage of MMC in rat fetuses with retinoic acid-induced MMC and demonstrated that these scaffolds adhere to the MMC and subsequently promote tissue coverage over the defect.⁶⁵ Although further development is needed, these studies support the therapeutic potential of a tissue engineering approach for prenatal coverage of MMC. Nonetheless, before less invasive fMMC coverage approaches are widely implemented, rigorous experimental testing and comparisons with open fMMC surgery techniques will be required to evaluate the risks and benefits of any new approaches to decrease the risks to the mother and fetus and to improve outcomes.

REFERENCES

- Adzick NS, Harrison MR. Fetal surgical therapy. *Lancet* 1994; **343**: 897–902.
- Danzer E, Sydorak RM, Harrison MR, Albanese CT. Minimal access fetal surgery. *Eur J Obstet Gynecol Reprod Biol* 2003; **108**: 3–13.
- Deprest JA, Flake AW, Gratacos E, et al. The making of fetal surgery. *Prenat Diagn* 2010; **30**: 653–67.
- Adzick NS. Open fetal surgery for life-threatening fetal anomalies. *Semin Fetal Neonatal Med* 2010; **15**: 1–8.
- Adzick NS, Thom EA, Spong CY, et al. A randomized trial of prenatal versus postnatal repair of myelomeningocele. *N Engl J Med* 2011; **364**: 993–1004.
- Danzer E, Flake AW. *In utero* repair of myelomeningocele: rationale, initial clinical experience and a randomized controlled prospective clinical trial. *Neuroembryol Ageing* 2006/2007; **4**: 165–74.
- McLone DG, Dias MS. The Chiari II malformation: cause and impact. *Childs Nerv Syst* 2003; **19**: 540–50.
- Charney EB, Rorke LB, Sutton LN, Schut L. Management of Chiari II complications in infants with myelomeningocele. *J Pediatr* 1987; **111**: 364–71.
- Worley G, Schuster JM, Oakes WJ. Survival at 5 years of a cohort of newborn infants with myelomeningocele. *Dev Med Child Neurol* 1996; **38**: 816–22.
- Oaks W, Gaskill S. Symptomatic Chiari malformations in childhood. In: Park TS, editor. *Spinal Dysraphism*. Boston: Blackwell Scientific Publications, 1992: 104–25.
- Hoffman HJ, Neill J, Crone KR, Hendrick EB, Humphreys RP. Hydroxyringomyelia and its management in childhood. *Neurosurgery* 1987; **21**: 347–51.
- Dias MS, McLone DG. Hydrocephalus in the child with dysraphism. *Neurosurg Clin North Am* 1993; **4**: 715–26.
- Rintoul NE, Sutton LN, Hubbard AM, et al. A new look at myelomeningoceles: functional level, vertebral level, shunting, and the implication for fetal intervention. *Pediatrics* 2002; **109**: 409–13.
- Pooh RK, Shiota K, Kurjak A. Imaging of the human embryo with magnetic resonance imaging microscopy and high-resolution transvaginal 3-dimensional sonography: human embryology in the 21st century. *Am J Obstet Gynecol* 2011; **204**: 77.e1–16.
- Danzer E, Rintoul NE, Crombleholme TM, Adzick NS. Pathophysiology of neural tube defects. In: Pollin R, Fox WW, Abman SH, editors. *Fetal and Neonatal Physiology*, 3rd edn. Philadelphia: W.B. Saunders Company, 2003: 1772–85.
- Mitchell LE, Adzick NS, Melchionne J, Pasquariello PS, Sutton LN, Whitehead AS. Spina bifida. *Lancet* 2004; **364**: 1885–95.
- Botto LD, Moore CA, Khoury MJ, Erickson JD. Neural-tube defects. *N Engl J Med* 1999; **341**: 1509–19.
- Czeizel AE, Dudas I. Prevention of the first occurrence of neural-tube defects by periconceptional vitamin supplementation. *N Engl J Med* 1992; **327**: 1832–5.
- MRC Vitamin Study Research Group. Prevention of neural tube defects: results of the medical research council vitamin study. *Lancet* 1991; **338**: 131–7.
- Williams LJ, Rasmussen SA, Flores A, Kirby RS, Edmonds LD. Decline in the prevalence of spina bifida and anencephaly by race/ethnicity: 1995–2002. *Pediatrics* 2005; **116**: 580–6.
- De Wals P, Tairou F, Van Allen MI, et al. Reduction in neural-tube defects after folic acid fortification in Canada. *N Engl J Med* 2007; **357**: 135–42.
- Hunt GM, Oakeshott P. Outcome in people with open spina bifida at age 35: prospective community based cohort study. *BMJ* 2003; **326**: 1365–6.
- Waitzman NJ, Romano PS, Scheffler RM. Estimates of the economic costs of birth defects. *Inquiry* 1994; **31**: 188–205.
- Patten B. Embryological stages in the establishing of myelogenesis with spina bifida. *Am J Anat* 1953; **93**: 365–95.
- Osaka K, Tanimura T, Hirayama A, Matsumoto S. Myelomeningocele before birth. *J Neurosurg* 1978; **49**: 711–24.
- Meuli M, Meuli-Simmen C, Hutchins GM, Seller MJ, Harrison MR, Adzick NS. The spinal cord lesion in human fetuses with myelomeningocele: implications for fetal surgery. *J Pediatr Surg* 1997; **31**: 448–52.
- Hutchins GM, Meuli M, Meuli-Simmen C, Jordan MA, Heffez DS, Blakemore KJ. Acquired spinal cord injury in human fetuses with myelomeningocele. *Pediatr Pathol Lab Med* 1996; **16**: 701–12.
- Sival DA, Guerra M, den Dunnen WF, et al. Neuroependymal denudation is in progress in full-term human foetal spina bifida aperta. *Brain Pathol* 2011; **21**: 163–79.
- Sival DA, Verbeek RJ, Brouwer OF, Sollie KM, Bos AF, den Dunnen WF. Spinal hemorrhages are associated with early neonatal motor function loss in human spina bifida aperta. *Early Hum Dev* 2008; **84**: 423–31.
- Sarnat HB. Ependymal reactions to injury. A review. *J Neuropathol Exp Neurol* 1995; **54**: 1–15.
- Korenromp MJ, Van Good JD, Bruinse HW, Kriek R. Early fetal movements in myelomeningocele. *Lancet* 1986; **1**: 917–8.
- Sival DA, Begeer JH, Staal-Schreinemachers AL, Vos-Niel JM, Beekhuis JR, Precht HF. Perinatal motor behaviour and neurological outcome in spina bifida aperta. *Early Hum Dev* 1997; **50**: 27–37.
- Luthy DA, Wardinsky T, Shurtleff DB, et al. Cesarean section before the onset of labour and subsequent motor function in infants with myelomeningocele diagnosed antenatally. *N Engl J Med* 1991; **324**: 662–6.
- Merrill DC, Goodwin P, Burson JM, Sato Y, Williamson R, Weiner CP. The optimal route of delivery for fetal myelomeningocele. *Am J Obstet Gynecol* 1998; **179**: 235–40.

35. Copp AJ, Bernfield M. Aetiology and pathogenesis of human neural tube defects: insights from mouse models. *Curr Opin Pediatr* 1994; **6**: 624–31.
36. Copp AJ, Greene ND, Murdoch JN. The genetic basis of mammalian neurulation. *Nat Rev Genet* 2003; **4**: 784–93.
37. Ehlers K, Strujs H, Merker HJ, Nau H. Spina bifida aperta induced by valproic acid and by all-trans-retinoic acid in the mouse: distinct differences in morphology and periods of sensitivity. *Teratology* 1992; **46**: 117–30.
38. Michejda M. Intrauterine treatment of spina bifida: primate model. *Z Kinderchir* 1984; **39**: 259–61.
39. Heffez DS, Aryanpur J, Rotellini NA, Hutchins GM, Freeman JM. Intrauterine repair of experimental surgically created dysraphism. *Neurosurgery* 1993; **32**: 1005–10.
40. Heffez DS, Aryanpur J, Hutchins GM, Freeman JM. The paralysis associated with myelomeningocele: clinical and experimental data implicating a preventable spinal cord injury. *Neurosurgery* 1990; **26**: 987–92.
41. Meuli M, Meuli-Simmen C, Yingling CD, et al. *In utero* surgery rescues neurological function at birth in sheep with spina bifida. *Nat Med* 1995; **1**: 342–7.
42. Meuli M, Meuli-Simmen C, Hutchins GM, et al. *In utero* repair of experimental myelomeningocele spares neurological function at birth. *J Pediatr Surg* 1996; **31**: 397–402.
43. Paek BW, Farmer DL, Wilkinson CC, et al. Hindbrain herniation develops in surgically created myelomeningocele but is absent after repair in fetal lambs. *Am J Obstet Gynecol* 2000; **183**: 1119–23.
44. Bouchard S, Davey MG, Rintoul NE, Walsh DS, Rorke LB, Adzick NS. Correction of hindbrain herniation and anatomy of the vermis following *in utero* repair of myelomeningocele in sheep. *J Pediatr Surg* 2003; **38**: 451–8.
45. Danzer E, Schwarz U, Wehrli S, Radu A, Adzick NS, Flake AW. Retinoic acid induced myelomeningocele in fetal rats: characterization by histopathological analysis and magnetic resonance imaging. *Exp Neurol* 2005; **194**: 467–75.
46. Danzer E, Kiddoo DA, Redden RA, et al. Structural and functional characterization of bladder smooth muscle in fetal rats with retinoic acid induced myelomeningocele. *Am J Physiol Renal Physiol* 2007; **292**: 197–206.
47. Danzer E, Radu A, Robinson LE, Volpe MV, Adzick NS, Flake AW. Morphologic analysis of the neuromuscular development of the anorectal unit in fetal rats with retinoic acid induced myelomeningocele. *Neurosci Lett* 2008; **430**: 157–62.
48. Danzer E, Zhang L, Radu A, et al. Amniotic fluid levels of glial fibrillary acidic protein in fetal rats with retinoic acid induced myelomeningocele: a potential marker for spinal cord injury. *Am J Obstet Gynecol* 2011; **204**: 178.e1–11.
49. Bruner J, Tulipan N, Richards W. Endoscopic coverage of fetal open myelomeningocele *in utero*. *Am J Obstet Gynecol* 1997; **176**: 256–7.
50. Farmer DL, von Koch CS, Peacock WJ, et al. *In utero* repair of myelomeningocele: experimental pathophysiology, initial clinical experience, and outcomes. *Arch Surg* 2003; **138**: 872–8.
51. Kohl T, Hering R, Heep A, et al. Percutaneous fetoscopic patch coverage of spina bifida aperta in the human – early clinical experience and potential. *Fetal Diagn Ther* 2006; **21**: 185–93.
52. Kohl T, Tchatcheva K, Weinbach J, et al. Partial amniotic carbon dioxide insufflation (PACI) during minimally invasive fetoscopic surgery: early clinical experience in humans. *Surg Endosc* 2010; **24**: 432–44.
53. Adzick NS, Sutton LN, Crombleholme TM, Flake AW. Successful fetal surgery for spina bifida. *Lancet* 1998; **352**: 1675–6.
54. Sutton LN, Adzick NS, Bilaniuk LT, Johnson MP, Crombleholme TM, Flake AW. Improvement in hindbrain herniation demonstrated by serial fetal magnetic resonance imaging following fetal surgery for myelomeningocele. *JAMA* 1999; **282**: 1826–31.
55. Bruner JP, Tulipan N, Paschall RL, et al. Fetal surgery for myelomeningocele and the incidence of shunt-dependent hydrocephalus. *JAMA* 1999; **282**: 1819–25.
56. Johnson MP, Sutton LN, Rintoul N, et al. Fetal myelomeningocele repair: short-term clinical outcomes. *Am J Obstet Gynecol* 2003; **189**: 482–7.
57. Danzer E, Johnson MP, Wilson RD, et al. Fetal head biometry following *in-utero* repair of myelomeningocele. *Ultrasound Obstet Gynecol* 2004; **24**: 606–11.
58. Danzer E, Johnson MP, Bebbington M, et al. Fetal head biometry assessed by fetal magnetic resonance imaging following *in utero* myelomeningocele repair. *Fetal Diagn Ther* 2007; **22**: 1–6.
59. Danzer E, Finkel RS, Rintoul NE, et al. Reversal of hindbrain herniation after maternal-fetal surgery for myelomeningocele subsequently impacts on brain stem function. *Neuropediatrics* 2008; **39**: 359–62.
60. Danzer E, Finkel R, Gerdes M, et al. The relationship of seizure activity and chronic epilepsy in early infancy and short-term neurodevelopmental outcome following fetal myelomeningocele closure. *Neuropediatrics* 2010; **41**: 140–3.
61. Danzer E, Gerdes M, Bebbington MW, et al. Lower extremity neuromotor function and short-term ambulatory potential following *in utero* myelomeningocele surgery. *Fetal Diagn Ther* 2009; **25**: 47–53.
62. Danzer E, Adzick NS, Rintoul NE, et al. Intradural inclusion cysts following *in utero* closure of myelomeningocele: clinical implications and follow-up findings. *J Neurosurg Pediatr* 2008; **2**: 406–13.
63. Danzer E, Gerdes M, Bebbington MW, Zarnow DM, Adzick NS, Johnson MP. Preschool neurodevelopmental outcome of children following fetal myelomeningocele closure. *Am J Obstet Gynecol* 2010; **202**: 450.e1–9.
64. Wilson RD, Johnson MP, Flake AW, et al. Reproductive outcomes after pregnancy complicated by maternal-fetal surgery. *Am J Obstet Gynecol* 2004; **191**: 1430–6.
65. Watanabe M, Jo J, Radu A, Kaneko M, Tabata Y, Flake AW. A tissue engineering approach for prenatal closure of myelomeningocele with gelatin sponges incorporating basic fibroblast growth factor. *Tissue Eng Part A* 2010; **16**: 1645–55.

18th Mediterranean Meeting of Child Neurology

In conjunction with the 5th Fred J. Epstein International Symposium
on New Horizons in Pediatric Neurology, Neurosurgery
and Neurofibromatosis

March 18–22, 2012
Ein Bokek, Dead Sea, Israel

Registration: www.childneuro2012.com